FREE CLINICAL GUIDE

The Emergence Profile Playbook

Six implant-site scenarios where a stock healing abutment falls short, and what to do chairside instead.



The implant is round. The tooth it replaces was not.

Everything between the implant platform and the contact points is tissue you either shape during healing or fight at delivery.

A cylindrical healing abutment produces a round, undersized cervical collar. At impression time the lab is asked to build the crown out to a natural cross-section, and the tissue has to be pushed into a shape it never healed into.

The result is what every restorative dentist recognises: blanching at delivery, a black triangle six months later, a buccal margin that keeps creeping. None of it was caused at delivery. It was caused on the day the tissue was given a round shape to heal into.

The alternative is to give the tissue its final cross-section on the day of placement, or at uncovering, and let it mature into that shape over 4 to 6 weeks. This is what an anatomical healing abutment does.

This playbook is about making that abutment in the chair, a fabrication step of under five minutes with practice, with composite you already own.



A composite anatomical healing abutment in the duplicate impression well. The profile the tissue healed into is transferred 1:1 to the lab.

READING

Bishara M, Kurtzman GM, Krause ES. Implant Restorations: Establishing a Proper Emergence Profile. *Compendium*, September 2020. Clinical figures by I. Vergoullis.

Cervico by VPI. Product feature, *British Dental Journal*, 2022.

Dounis T, Jimenez Ortiz V. Dental implants placed in fresh human extraction sockets without osteotomy: a case series. *Clin Exp Dent Res* 2025;11(3):e70159. Anatomical healing abutments made with Cervico.

Pelekanos S, Vergoullis I. Clinical advances in implant transmucosal contouring for single implant sites. *Int J Periodontics Restorative Dent* 2023;43(3):301–310.

Mattheos N, Vergoullis I, Janda M, Miseli A. The implant supracrestal complex and its significance for long-term successful clinical outcomes. *Int J Prosthodont* 2021;34(1):88–100.

Vergoullis I, et al. Customized implant emergence profile using the VPI management system: an innovative approach. *Clin Oral Implants Res* 2017;28(Suppl 14):343.

Samad AA. Optimizing soft tissue emergence profile around one-piece dental implants. *Erbil Dent J* 2024;7(2):174–178. Chairside profiles made with the Cervico mold, 137 implants.

IN THIS GUIDE

Six scenarios, one page each: the situation, where non-customizable healers fail, the chairside answer.

TWO CASES

A severe buccal recession site and an adjacent premolar and molar, both restored without soft-tissue grafts.

THE PROTOCOL

Evaluate, fabricate, deliver, impress or scan. The chairside fabrication step takes under five minutes with practice; healing and impression timing are separate clinical decisions.

SCENARIO 1 OF 6 · DEPTH

01

Subcrestal placement

THE SITUATION

The platform sits 1 to 3 mm below the crest, for biologic width, for a thin crest, or for aesthetics. The healing abutment has to bridge that depth before it can shape anything.

WHERE NON-CUSTOMIZABLE HEALERS FAIL

Stock healers come in different heights. You choose between a collar that supports the tissue and a margin that sits exposed. Neither emerges anatomically from a subcrestal platform.

THE CHAIRSIDE ANSWER

The Premium Mold sets insertion depth in 1 mm increments through the VPI insert. The Essential Mold covers crestal to 3 mm subcrestal from one set of wells. Either way the abutment emerges anatomically from the platform, whatever the depth.



Composite abutments made in the same well at different insertion depths. One system covers crestal to 3 mm subcrestal.

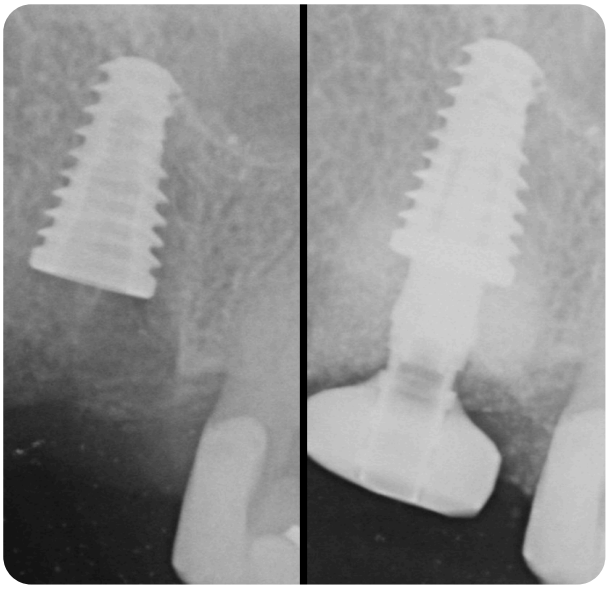

An implant placed well below the crest, before and with its anatomical composite healing abutment: the same well, a longer transmucosal part, an anatomical emergence from that depth. Case by Dr Alessandro Perucchi and Dr Cristian Scognamiglio.

02

Eccentric implant position

THE SITUATION

The implant is not centred under the planned crown. Typical in the aesthetic zone, in narrow ridges and wherever the bone dictated the position more than the prosthetics did.

WHERE NON-CUSTOMIZABLE HEALERS FAIL

The collar is centred on the fixture, so the profile is centred in the wrong place. The crown then has to cantilever the emergence buccally or lingually over tissue that healed around a centred cylinder.

THE CHAIRSIDE ANSWER

Off-centred wells shift the anatomical profile buccally or lingually relative to the connection. The Essential Mold has them built in; the Premium Kit includes an off-centred silicone insert with 12 more wells. The tissue heals around the profile the crown will actually have.

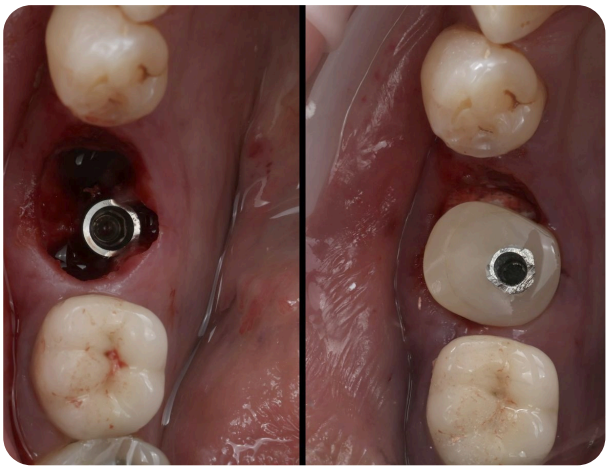

Immediate placement in a lower molar socket: the implant sits off-centre in the socket, and the custom abutment carries the molar outline with the access hole off-centre. Case by Dr Alessandro Perucchi and Dr Cristian Scognamiglio.



The anatomical tab identifies the profile shape and its position relative to the implant before the well is chosen. The centred and off-centred bore on the tab dictate the corresponding position of the osteotomy and the implant.

Immediate placement in a molar socket

03

THE SITUATION

A multi-rooted socket and a 4 to 5 mm implant. The gap between the two is the problem, and the soft tissue over it has nowhere to go but down.

WHERE NON-CUSTOMIZABLE HEALERS FAIL

A cylindrical abutment seals nothing. The tissue collapses into the gap, the graft, if there is one, is exposed, and the papillae you had at extraction are gone by uncovering.

THE CHAIRSIDE ANSWER

A molar-shaped composite abutment seals the socket on the day and supports the existing architecture. Prof. Nitzan Bichacho: “In situations of immediate implant placement, especially in posterior teeth, Cervico enables me to perfectly seal the socket and support the existing soft tissue architecture.”

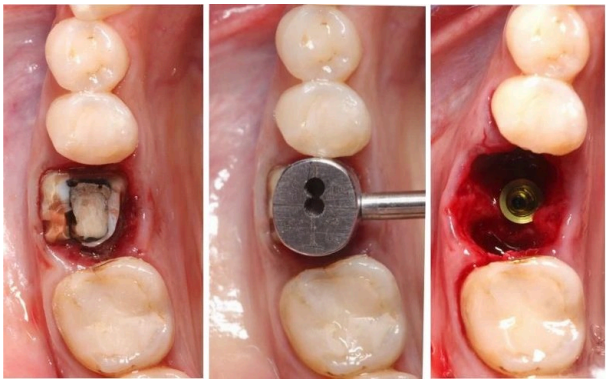

Immediate placement in a lower molar socket: the failing tooth, the Cervico Guide tab evaluating the site before drilling, and the implant in the fresh socket with the gap around it. Case by Dr Stavros Pelekanos.

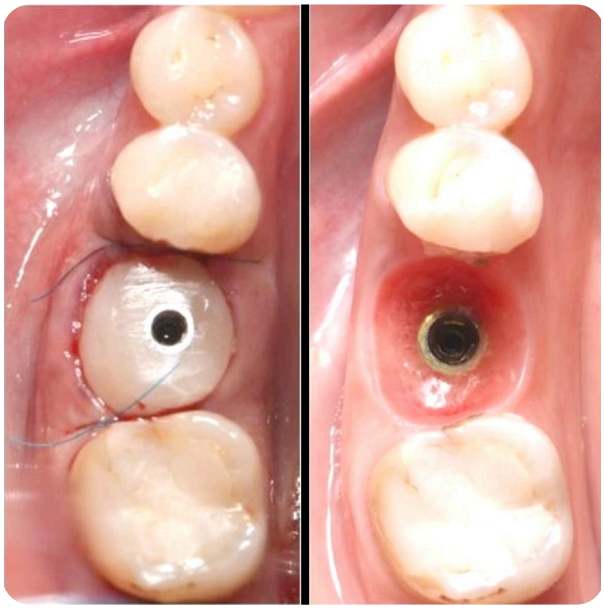

The same visit and after: the custom composite abutment sealing the socket, sutured; and the emergence profile after its removal.

Thin buccal tissue or existing recession

04

THE SITUATION

No bone and no soft tissue buccally after a cyst, a fractured root or a failed tooth. The site healed by secondary intention and the buccal wall is a memory.

WHERE NON-CUSTOMIZABLE HEALERS FAIL

A stock abutment can jeopardise thin tissue by applying undesired pressure. Even if a connective tissue graft is placed, the stock healer can fight against the space the tissue needs to grow into.

THE CHAIRSIDE ANSWER

Composite can be modified chairside according to the needs of the case: added to or reduced. Build a convex buccal contour where support is needed, or a concave one where a graft was placed. The healing abutment stops being a spacer and becomes the thing shaping the outcome. Full case on page 9.



Severe buccal recession before extraction. After healing: no bone, no soft tissue buccally.

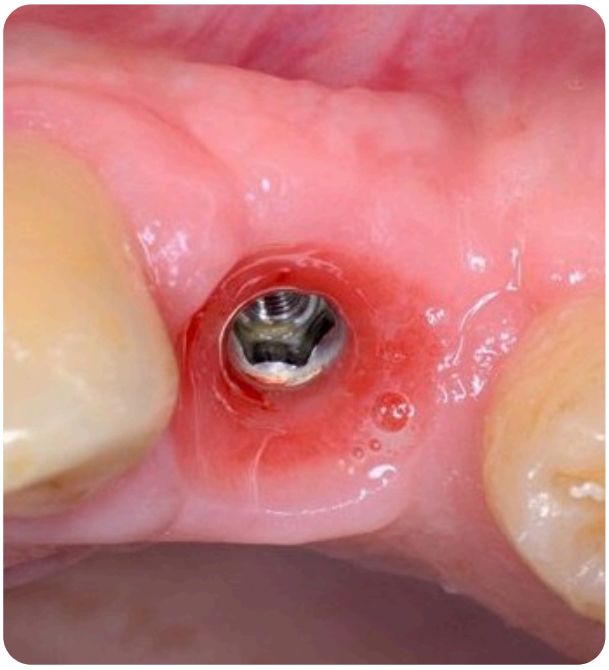

Three months after placement: an anatomical emergence profile without a connective tissue graft.

05

Limited mesio-distal space

THE SITUATION

Post-orthodontic sites, congenitally missing laterals, a premolar site closed to 6 mm. The restoration has to fit between two teeth that are not moving.

WHERE NON-CUSTOMIZABLE HEALERS FAIL

A round collar in a narrow site leaves either open embrasures or crushed papillae, and you find out which at impression, after the tissue has healed.

THE CHAIRSIDE ANSWER

Measure before you drill. The Guide's eight cylindrical tabs (5 to 12 mm) confirm the mesio-distal space and mark the osteotomy. The anatomical tabs then pick the smallest profile that still supports both papillae independently.



A cylindrical tab measures the prosthetic space intraorally, then guides the initial trephination as a stent.



Eight cylindrical tabs, 5 to 12 mm, on the Guide handle. Profile evaluation, osteotomy marking and space assessment in one instrument.

When the healing abutment has to become the provisional

06

THE SITUATION

Aesthetic zone. The patient wants a tooth today, or the tissue needs a provisional to hold what surgery created.

WHERE NON-CUSTOMIZABLE HEALERS FAIL

A stock healing abutment and a provisional are different parts. Swapping one for the other disturbs the tissue you just shaped, and the provisional starts from a round collar. Moreover, repeated prosthetic connections and disconnections can lead to bone and soft-tissue recession.

THE CHAIRSIDE ANSWER

Composite converts. Build the provisional on the abutment already in the mouth, same emergence, no second insertion. The subgingival contour the tissue healed into is the contour the provisional carries.



Immediate implant at a central incisor. Left: the Cervico healing abutment with its temporary abutment still uncut. Right: the same part converted chairside into the provisional. Case by Dr Alessandro Perucchi and Dr Cristian Scognamiglio.

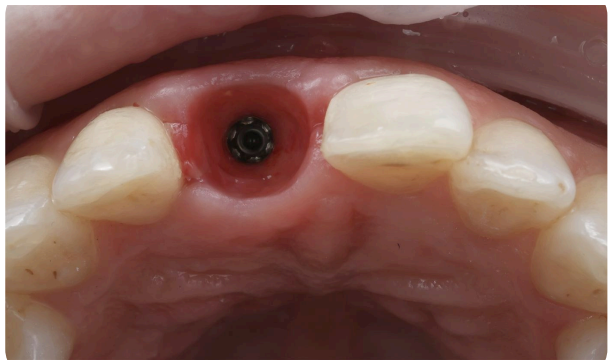

Four weeks later, provisional removed: the emergence profile the tissue healed into, ready for the final crown. Full case at vpicervico.com.

A deficient buccal site, treated without a soft-tissue graft

An edentulous site after extraction of a tooth with a small cyst. Eight weeks of healing by secondary intention left no bone and no soft tissue on the buccal side.



Extraction and cyst enucleation. No bone or soft tissue buccally; the site is left to heal by secondary intention.

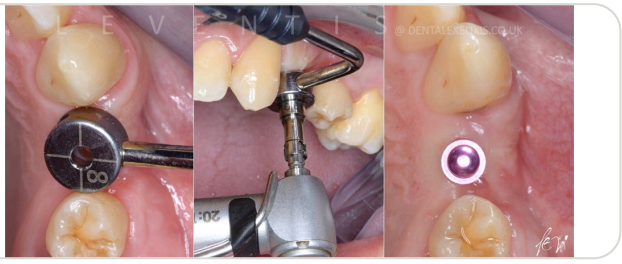

The Guide's cylindrical tab measures the prosthetic space, then guides the initial trephination as a stent.

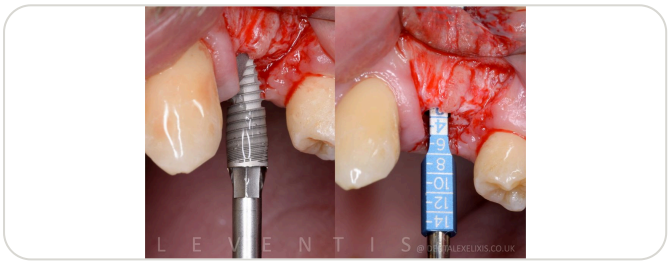

3.75 × 11.5 mm implant, 1 mm subcrestal, under a full-thickness flap. Depth gauge reads depth and tissue thickness.

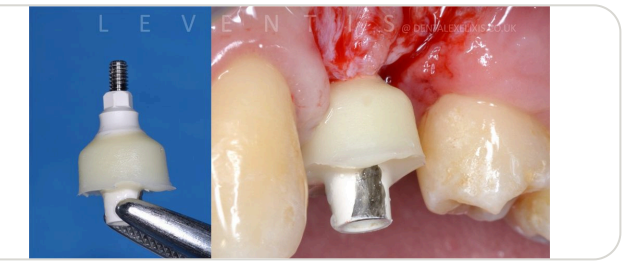

Custom Essential healing abutment in flowable composite, shaped to support the missing buccal tissue, fitted.

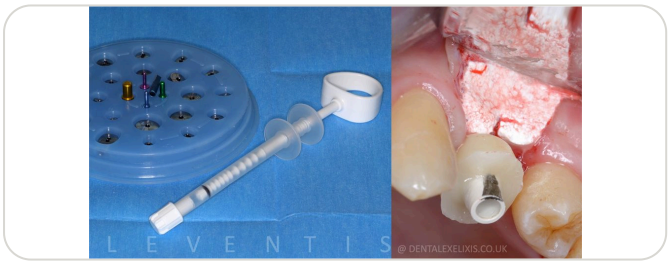

0.3 cc resorbable b-TCP putty around the abutment. No membrane, no soft-tissue graft.



Three months: anatomical emergence profile, ready for prosthetics.

PROTOCOL

Extraction and cyst enucleation · 8 weeks secondary healing · Guide as stent · Full-thickness flap · Keystone Paltop Dynamic 3.75 × 11.5, 1 mm subcrestal · Essential healing abutment, Elsodent Purefill Bio+ · Powerbone Putty 0.3 cc · SilverPlug · PTFE 5-0

WHAT IT SHOWS

The healing abutment was shaped for the tissue that was missing, not the tissue that was there. This case combined a custom healing abutment with 0.3 cc of b-TCP putty; no barrier membrane and no soft-tissue graft were used. At three months the site had an aesthetic, functional and biologically sound emergence profile, with no second surgery.

Case and images: Dr. Minas Leventis. Full case at vpicervico.com.

A premolar and a molar, flapless pilot through the Guide, no membranes

Long-term edentulism with over-erupted opposing teeth. Two adjacent implants, one site with a medium and one with a thin tissue phenotype, where the emergence profile had to be built, not preserved. Simple and effective surgery.

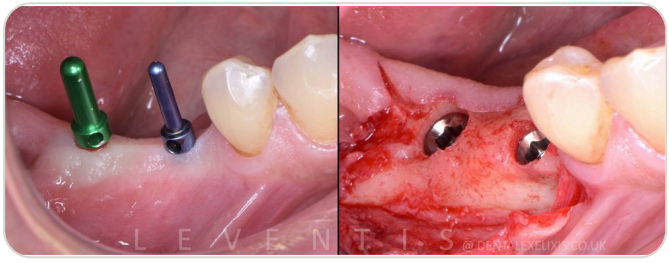

Pilot trephinations, flapless, through the Cervico tabs used as a surgical stent. Pins verify position, then the flap is raised.

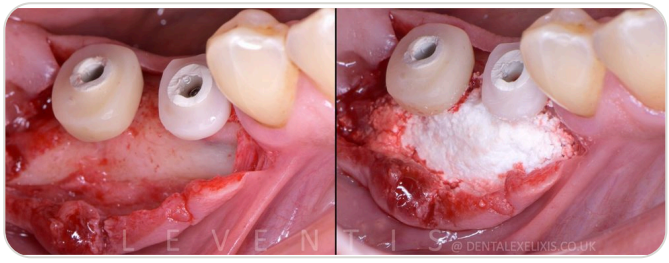

Two custom abutments fitted; b-TCP / calcium sulfate graft around them, no membrane.



Flap positioned buccally with small Palacci incisions, sutured 5-0. Prosthetic canal sealed with SilverPlug.



Two weeks post-op: uneventful healing.

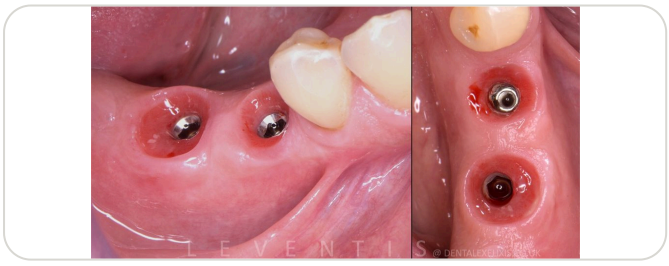

Three months: adequate tissue shape, quality and volume re-established, ready for the lab. No additional procedures.

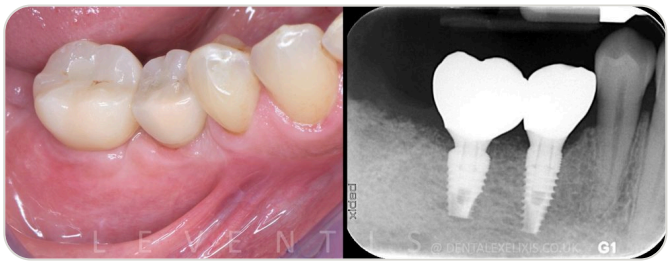

Screw-retained crowns seated. They read short because the opposing teeth over-erupted during edentulism.

PROTOCOL

Flapless pilot trephination through Cervico tabs · Pins to verify · Full-thickness flap · Keystone Paltop Dynamic implants · Depth gauge, 4 mm platform to margin · Custom healing abutments from Guide and Mold · b-TCP / calcium sulfate · SKD monofilament 5-0 · SilverPlug · Screw-retained crowns

WHAT IT SHOWS

Proper emergence profile and soft tissue contours on an adjacent premolar and molar without soft tissue grafts or barrier membranes. The Guide did three jobs before the drill touched bone: profile selection, osteotomy marking, and space verification.

Case and images: Dr. Minas Leventis. Laboratory: Phill Reddington, Beever Dental Laboratory. Full case at vpicervico.com.

Four steps. Fabrication in under five minutes with practice.



01

Evaluate

Seat the Guide tray. Try anatomical tabs until one matches the site: 12 shapes across four tooth groups, three sizes each. Read the code on the tab.



02

Fabricate

Thread a temporary abutment into the matching well of the Mold. Fill with a nano-hybrid flowable composite. Light cure.

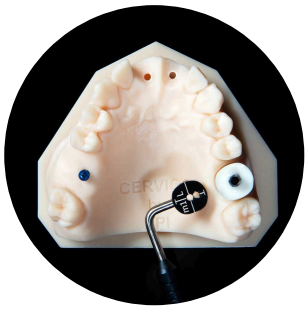

03

Deliver

Unscrew, polish, seat, torque to the implant manufacturer's value. Let the implant integrate, or if placed at uncovering, allow the tissue to mature for 4 to 6 weeks.



04

Impress / scan

Use the same well to fabricate a duplicate impression post for open or closed tray, or scan directly.

MATERIALS

Use a **nano-hybrid flowable composite**. It cures reliably through the silicone wells and polishes to a smooth tissue-contact surface.

Avoid bis-acryl. It is brittle, polishes badly and fractures at the margin.

REUSE AND STERILISATION

The metal base, the silicone insert, the Guide tray and every tab autoclave at **134 °C**. Both molds are reusable for the life of the practice; only the composite and the temporary abutment are consumed per case.



The Cervico Guide. The tab seats over the site: cylindrical tabs measure the space and mark the osteotomy, anatomical tabs choose the cervical profile.

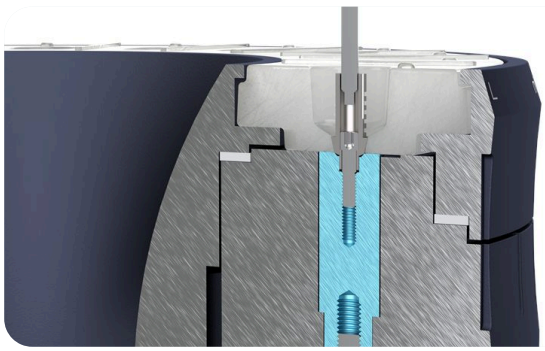

Inside the well: the abutment seats to a fixed depth and the silicone gives the composite its anatomical cervical shape.

WHICH CERVICO

It depends on how you take impressions.



PREMIUM KIT

Conventional impressions, assistant pre-fabrication

Guide + Premium Mold. VPI inserts lock orientation and set depth in 1 mm steps. True 1:1 duplicate impression post.



ESSENTIAL KIT

Intra-oral scanning, any implant system

Guide + Essential Mold. 24 wells, centred and off-centred, universal stock-analog compatibility. Position by hand, scan the result.



ESSENTIAL MOLD

Start this month, add the Guide later

The mold alone. Select the well by eye. The most affordable way into anatomical healing abutments.

	Premium Kit	Essential Kit
Includes the Cervico Guide	Yes	Yes
Implant compatibility	Via VPI Prosthetic Connection Inserts	Universal, any stock analog
Insertion depth control	1 mm increments	Manual positioning
Fixed buccal orientation	Yes, hex flat always faces buccal	Manual orientation
Impression transfer	Exact 1:1 duplicate post, open or closed tray	Best paired with an intra-oral scanner
Sterilisable, reusable	Yes	Yes

NOT SURE?

Take the 30-second finder at vpicervico.com/find-your-cervico

VP Innovato Holdings LTD · Poseidonos 4A, Aradippou 7101, Larnaca, Cyprus · info@vpicervico.com · +357 99 883 898 · US +1 888 203 3246 · vpicervico.com

Cervico is a registered medical device. Follow the Instructions for Use for sterilisation and clinical protocol. Clinical images courtesy of Dr. Minas Leventis, Dr. Stavros Pelekanos, Dr. Alessandro Perucchi and Dr. Cristian Scognamiglio. © 2026 VP Innovato Holdings LTD.